

This is an Open Access article licensed under the terms of the Creative Commons Attribution-NonCommercial 3.0 Unported license (CC BY-NC) (www.karger.com/OA-license), applicable to the online version of the article only. Distribution permitted for non-commercial purposes only.

Case of Small Vessel Disease Associated with COL4A1 Mutations following Trauma

Joao McONeil Plancher^a Robert B. Hufnagel^b Achala Vagal^c
Katrina Peariso^d Howard M. Saal^b Joseph P. Broderick^a

^aDepartment of Neurology and Rehabilitation Medicine, University of Cincinnati College of Medicine, Comprehensive Stroke Center at UC Neuroscience Institute, ^bDivision of Human Genetics, Cincinnati Children's Hospital, ^cDepartment of Radiology, University of Cincinnati College of Medicine, and ^dDivision of Neurocritical Care, University of Cincinnati Health, Neurotrauma Center at UC Neuroscience Institute, Cincinnati, Ohio, USA

Key Words

COL4A1 · Cerebral small vessel disease · Heterozygous putatively pathogenic mutation

Abstract

With this case report, we would like to heighten the awareness of clinicians about COL4A1 as a single-gene disorder causing cerebral small vessel disease and describe a previously unreported pathogenic missense substitution in COL4A1 (p.Gly990Val) and a new clinical presentation. We identified a heterozygous putatively pathogenic mutation of COL4A1 in a 50-year-old female with a history of congenital cataracts and glaucoma who presented with multiple diffusion-positive infarcts and areas of contrast enhancement following mild head trauma. We believe that this presentation of multiple areas of acute brain and vascular injury in the setting of mild head trauma is a new manifestation of this genetic disorder. Imaging findings of multiple acute infarcts and regions of contrast enhancement with associated asymptomatic old deep microhemorrhages and leukomalacia in adults after head trauma should raise a high suspicion for a COL4A1 genetic disorder. Radiographic patterns of significant leukoaraiosis and deep microhemorrhages can also be seen in patients with long-standing vasculopathy associated with hypertension, which our patient lacked. Our findings demonstrate the utility of genetic screening for COL4A1 mutations in young patients who have small vessel vasculopathy on brain imaging but who do not have significant cardiovascular risk factors.

© 2015 S. Karger AG, Basel

Introduction

Mutations in *COL4A1* encoding the type IV collagen alpha-1 chain, an integral basement membrane protein, have been recently identified as a cause of small vessel cerebral vascular disease. *COL4A1* mutations are associated with a wide range of phenotypes that include both ischemic and hemorrhagic strokes, migraines, leukomalacia, nephropathy, hematuria, chronic muscle cramps, and ocular anterior segment diseases including congenital cataracts, glaucoma, and Axenfeld-Rieger anomalies [1]. We describe a unique presentation of small vessel disease associated with *COL4A1* mutation in a middle-aged woman after mild head trauma.

Case Report

A 50-year-old female with a history of congenital cataracts, glaucoma, cerebral palsy, and acquired neurogenic bladder suffered a mild head trauma after a fall from standing height. Although she was initially cognitively intact and oriented, she became confused and developed right-sided weakness after several minutes. A neurological examination demonstrated severe spastic dysarthria, roving eye movements, bilateral asymmetric weakness of her arms and legs (right limb greater than left), and increased appendicular tone (lower extremities greater than upper).

An initial head CT showed confluent periventricular white matter abnormalities and the evolution of scattered punctate hemorrhages (fig. 1). A CT angiogram of the head and neck was unremarkable. An MRI of the brain revealed extensive abnormalities (fig. 2) including confluent periventricular white matter diseases, new infarction independent of hemorrhage, multiple scattered hemorrhages, and contrast-enhancing periventricular white matter. Cerebrospinal fluid (CSF) studies showed an elevated protein level (87 mg/dl), an IgG index of 0.5, and absent oligoclonal bands. Serum and CSF viral studies were normal. Serum autoimmune panels were normal except for a mildly elevated Sjögren's syndrome antinuclear antibody ratio (1.25; normal range 0–0.9) with unknown significance. Notably, her sister was diagnosed with progressive multiple sclerosis (MS) at the age of 26 years.

With the acute presentation of neurologic symptoms and a family history of demyelinating disease, acute hemorrhagic leukoencephalopathy secondary to underlying demyelinating disease was considered, and high-dose methylprednisolone therapy was initiated empirically. On day 3, the patient acutely became less responsive. A repeat head CT revealed increased new intraventricular hemorrhagic foci (fig. 3). A repeat brain MRI 5 days later showed an interval increase in the multifocal and periventricular hemorrhagic foci with new intraventricular hemorrhage without any change in white matter hyperintensities (fig. 3).

Although the numerous areas of acute contrast enhancement were atypical, we considered the possibility of monogenic small vessel vasculopathies. Given the additional history of congenital cataracts and glaucoma, genetic syndromes involving ocular anterior segment dysgenesis, neuronal dysplasia or degeneration, and vasculopathy were considered (particularly *COL4A1*-associated diseases). *COL4A1* sequencing was performed, revealing a missense substitution (c.2969G>T; p.Gly990Val; NM_001845) within the triple helical G-X-Y domain, located within the splice acceptor site of exon 36. This previously unreported mutation is located in a residue conserved in mammals, avians, fish (including *Danio rerio*), and *Caenorhabditis elegans*, and is predicted to be damaging by MutationTaster (www.mutationtaster.org), polyphen-2 (genetics.bwh.harvard.edu/pph2), SIFT, and PROVEAN (http://sift.jcvi.org). The Grantham score was 109, and the PHRED score was 32 (cadd.gs.washington.edu). A splice site alteration was predicted at this position by Human

Splice Finder (www.umd.be/HSF). Exon 37 is in-frame with exon 35; therefore, skipping of exon 36 and deletion of residues 990–1019 are predicted. This variant has not been reported in the 1000 Genomes Project (www.1000genomes.org), Exome Variant Server (evs.gs.washington.edu/EVS), or Exome Aggregation Consortium (exac.broadinstitute.org/). Other pathogenic mutations are reported in glycines within the Gly-X-Y triple helical domain of *COL4A1* and other collagenopathy-associated genes [2, 3]. The sequencing was negative for other genetic causes of anterior segment dysgenesis, including *B3GALTL*, *BMP4*, *CYP11B1*, *FOXC1*, *FOXC2*, *FOXE3*, *LAMB2*, *PAX6*, *PITX2*, and *PITX3* [4]. Therefore, we considered *COL4A1* the cause of her cataracts and small vessel disease by mutation in the triple helical domain critical for forming collagen type 4 $\alpha 1$ $\alpha 1$ $\alpha 2$ heterotrimers [3]. Genetic testing was declined by her asymptomatic parents, asymptomatic son, and her sister with MS. The lack of any family history of ocular anterior segment dysgenesis and a lack of prior reports of incomplete penetrance in *COL4A1*-associated disease suggest that the mutation arose de novo in this patient.

Discussion

COL4A1 variants were first reported in 2005 to cause an autosomal dominant disorder affecting the structural integrity of the basement membrane and resulting in congenital ocular malformation and in leukoencephalopathy, small vessel disease, the rupture of intracranial small arterioles leading to cerebral hemorrhages and leukoaraiosis in neonatal, pediatric, or middle-aged patients [2, 5, 6]. Brain hemorrhages in those with *COL4A1* have been associated with mild trauma, including birth trauma, and are thought to be caused by the increased susceptibility to stress-induced arterial and arteriolar rupture [1].

This patient had extensive multifocal areas of diffusion restriction and contrast enhancement that indicated multiple areas of blood-brain barrier breakdowns, which were temporally related to her mild head trauma. These unique acute imaging findings occurred in the setting of extensive asymptomatic leukoencephalopathy and microhemorrhages. Based on the spectrum of imaging findings, differential diagnoses also included acute disseminated hemorrhagic encephalomyelitis, inflammatory leukoencephalopathy, and inflammatory amyloid disease (although the microhemorrhages were not cortical). However, while her diagnosis was not determined until she presented with multiple strokes following mild head trauma, much of her brain imaging changes were due to ischemic and small hemorrhagic events over a long duration. Notably, her diagnosis of cerebral palsy was likely the result of a chronic, slowly progressive presentation of congenital white matter or small vessel disease. Patients with *COL4A1* mutations have presented with infantile hemiparesis with the brain injury thought to occur from mild head trauma during delivery [2]. Family members, including her sister, refused further genetic testing because of cost. Whether this *COL4A1* mutation occurred de novo or is present in asymptomatic family members or her sister with the previous diagnosis of progressive MS remains uncertain.

In conclusion, diagnostic indications for this presentation of *COL4A1*-associated vasculopathy are extensive leukoencephalopathy with microhemorrhages in a middle-aged patient who lacks cardiovascular risk factors, with a history of congenital cataracts and glaucoma. The imaging findings of multiple regions of blood-brain barrier disruption represent a new presentation for *COL4A1* mutations and highlight the importance of brain imaging in patients with *COL4A1*-associated disease, as prior ischemic changes in the brain due to small vessel disease may be asymptomatic. However, some of the phenotypes associated with these mutations may go unrecognized.

Disclosure Statement

J.M. Plancher reports no disclosure. J.P. Broderick received research money from the Department of Neurology from Genentech for the PRISMS Trial; he also travelled to the Australian stroke conference, paid for by Boehringer Ingelheim. K. Peariso reports a single paid panel discussion for UCB. A. Vagal received research grants from CTSA 8 UL1 TR000077-05 and Genentech, Inc. R.B. Hufnagel and H.M. Saal report no disclosures related to this paper.

References

- 1 Lanfranconi S, Markus HS: COL4A1 mutations as a monogenic cause of cerebral small vessel disease: a systematic review. *Stroke* 2010;41:e513–e518.
- 2 Gould DB, Phalan FC, van Mil SE, Sundberg JP, Vahedi K, Massin P, et al: Role of COL4A1 in small-vessel disease and hemorrhagic stroke. *N Engl J Med* 2006;354:1489–1496.
- 3 Carter EM, Raggio CL: Genetic and orthopedic aspects of collagen disorders. *Curr Opin Pediatr* 2009;21:46–54.
- 4 Reis LM, Semina EV: Genetics of anterior segment dysgenesis disorders. *Curr Opin Ophthalmol* 2011;22:314–324.
- 5 Gould DB, Phalan FC, Breedveld GJ, van Mil SE, Smith RS, Schimenti JC, et al: Mutations in Col4a1 cause perinatal cerebral hemorrhage and porencephaly. *Science* 2005;308:1167–1171.
- 6 Rannikmae K, Davies G, Thomson PA, Bevan S, Devan WJ, Falcone GJ, et al: Common variation in COL4A1/COL4A2 is associated with sporadic cerebral small vessel disease. *Neurology* 2015;84:918–926.

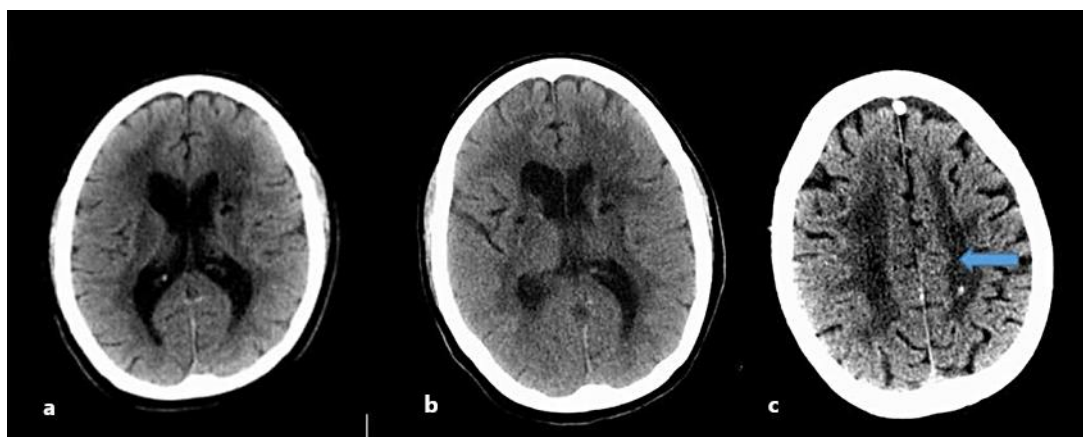


Fig. 1. An initial head CT made at an outside facility and at our institution shows a middle-aged woman presenting with confusion and weakness. **a** Initial outside facility head CT. **b, c** Initial head CT performed at our institution. Confluent hypoattenuation of the cerebral white matter with superimposed focal hypodensities involving the basal ganglia. A small punctate hyperdensity was a concern for hemorrhage (arrow).

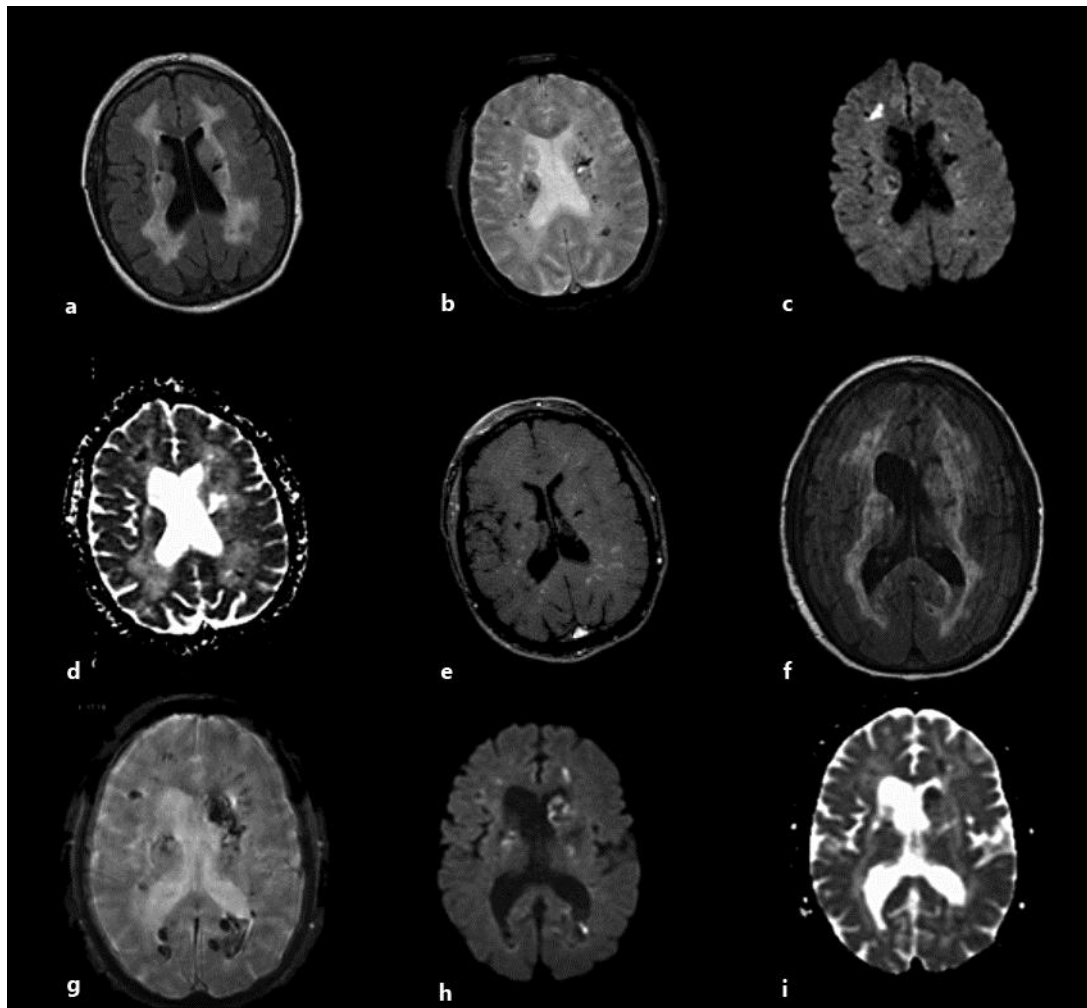


Fig. 2. MRI sequences of a middle-aged woman with small vessel disease associated with *COL4A1* mutations. Outside facility MRI sequences are shown in **a–e**. **a** Fluid-attenuated inversion recovery images demonstrate extensive confluent areas of periventricular white matter signal abnormality. **b** A gradient echo sequence shows multiple, scattered areas of small hemorrhages. **c, d** Diffusion-weighted images and the apparent diffusion coefficient demonstrate concomitant areas of acute ischemia. The ischemic areas are in addition to the multiple hemorrhagic foci, as seen in right frontal periventricular white matter. **e** T1 contrast-enhanced images demonstrating multiple, enhancing foci in the periventricular white matter signal abnormality. Repeat MRI on day 5 after clinical worsening is shown in **f–i**. **f** Persistent diffuse confluent areas of periventricular white matter signal abnormality. **g** Progressive multifocal subcortical and periventricular hemorrhagic foci with new intraventricular hemorrhage. **h, i** Multiple hemorrhagic foci with diffusion-weighted imaging hyperintensity and apparent diffusion coefficient darkness.

Plancher et al.: Case of Small Vessel Disease Associated with COL4A1 Mutations following Trauma

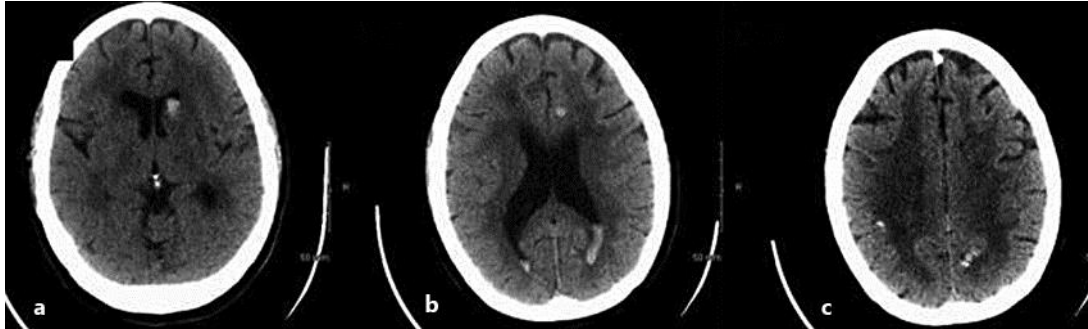


Fig. 3. Noncontrast head CT after the patient decompensated. Hospital day 3 head CT images (a–c). There are extensive hemorrhagic foci along with intraventricular hemorrhages (increased since baseline head CT). Extensive patchy and confluent low attenuation in the periventricular as well as the deep white matter is again identified.