

Cerebrovasc Dis 2013;35:593–594

DOI: [10.1159/000351520](https://doi.org/10.1159/000351520)**COL4A1 Mutation Revealed by an Isolated Brain Hemorrhage**Astrid Corlobe^a, Elisabeth Tournier-Lasserre^c, Manuele Mine^c,
Nicolas Menjot de Champfleury^b, Clarisse Carra Dalliere^a,
Xavier Aygnac^a, Pierre Labauge^a, Caroline Arquizan^aServices de ^aNeurologie and ^bNeuroradiologie, Hôpital Gui de
Chauliac, Montpellier, and ^cLaboratoire de Génétique, Groupe
Hospitalier Lariboisière-Fernand Widal, INSERM UMR-S740,
Paris, France*Introduction*

Ten to fifteen percent of strokes are related to an intracerebral hemorrhage (ICH). Etiologies are mainly arterial hypertension, amyloid deposition, and vascular malformations. In cases of a young age without vascular risk factors and vascular malformations, a genetic cause has to be suspected, especially a mutation in the gene coding for type IV collagen alpha 1 (*COL4A1*) [1].

We report a *COL4A1* gene mutation in a 45-year-old woman with an isolated ICH in the absence of any other MRI abnormality, which further extends the clinical spectrum of *COL4A1* mutations.

Case Report

A 45-year-old woman, without vascular risk factors, especially hypertension, or any medical history presented a coital thunder-clap headache, followed by a right hemiparesis, hemihypoesthesia, and dysarthria. Usual biological analyses, including renal function, were normal. Brain MRI revealed an isolated ICH of the left putamen and internal capsule without any other abnormalities (fig. 1a, b). Microbleeds and leukoencephalopathy were absent. Brain CT scan did not find any calcification. Cerebral angiography was normal. Blood pressure monitoring, electrocardiography, transthoracic echocardiography, Holter monitoring, and a stress test were normal. The ophthalmological examination showed no retinal arteriolar tortuosity or cataracts. Renal ultrasound was normal. A second brain MRI performed 3 months later only showed the sequelae of ICH (fig. 1c, d). Inquiries among relatives were strictly negative. However, because of this unexplained and isolated ICH in a young adult, a genetic cause was strongly suspected.

The entire *COL4A1* gene was sequenced and a heterozygous G-to-A transition (c.2063G>A) was identified in exon 28, leading to the replacement of a highly conserved glycine residue by aspartic acid at position 688 (p.G688D) within the triple-helix domain. This mutation, never described to date, was not found in a panel of 288 control chromosomes of ethnically matched controls, and it is not present in the Exome Variant database or dbSNP137. It was predicted to be deleterious by SIFT, Polyphen, and alignGVD software.

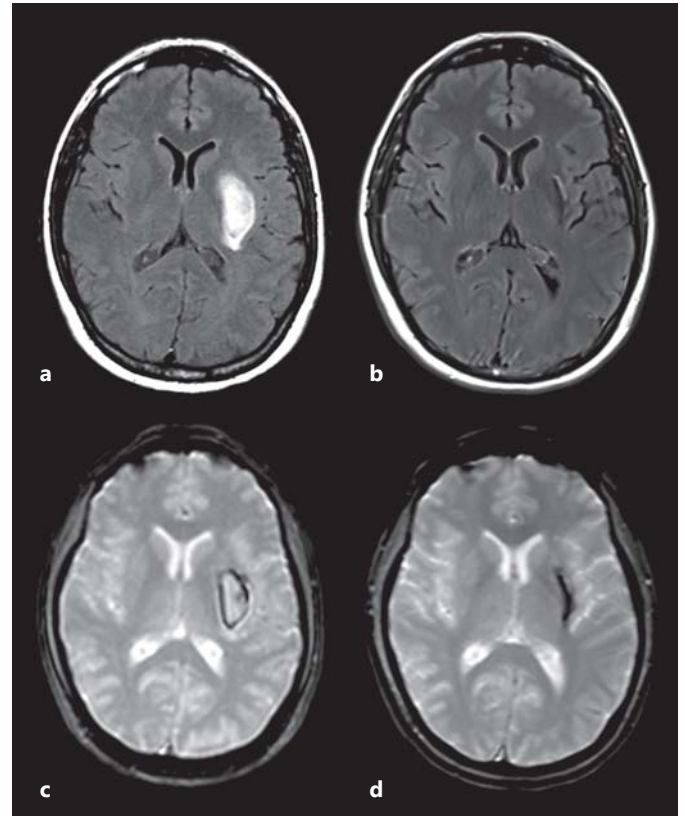


Fig. 1. Brain MRI. Flair sequence (a) and gradient echo sequence (b). Initial MRI showing an ICH of the left putamen and internal capsule without any other abnormalities. Flair sequence (c) and gradient echo sequence (d). Sequelae of ICH on a further MRI 3 months later.

Discussion

The spectrum of *COL4A1*-related disorders includes perinatal cerebral hemorrhage and porencephaly [2], cerebral small vessel disease with retinal arteriolar tortuosity and leukoencephalopathy [3], HANAC syndrome (Hereditary Angiopathy, Nephropathy, Aneurysms, and Muscle Cramps) and other eye abnormalities, including the Axenfeld-Rieger anomaly and cataract. A frequent white matter involvement is reported [3, 4]. Interestingly, some HANAC patients may have a normal brain MRI. However, except for one patient who suffered from migraine, these patients were free from neurologic symptoms [5, 6].

Recently, Weng et al. [7] reported *COL4A1* variants in 2/96 patients with sporadic ICH. Their phenotype was not described in

detail, but they did not seem to present an isolated deep ICH, as did our patient. Indeed, one 73-year-old patient had lobar ICH and microbleeds on his cerebral MRI, and the other patient with deep ICH suffered from hypertension.

Our report extends the clinical and MRI phenotypes of patients with pathogenic *COL4A1* mutation. These data strongly suggest that *COL4A1* genetic screening should be proposed in young patients with an isolated ICH of undetermined etiology, even without any other MRI abnormalities (microbleeds, leukoencephalopathy), or any family history of neurological manifestations.

Disclosure Statement

No financial disclosure.

References

- 1 Lanfranconi S, Markus HS: COL4A1 mutations as a monogenic cause of cerebral small vessel disease: a systematic review. *Stroke* 2010;41:e513–e518.
- 2 Gould DB, Phalan FC, Van Mil SE, et al: Role of COL4A1 in small-vessel disease and hemorrhagic stroke. *N Engl J Med* 2006;354:1489–1496.
- 3 Plaisier E, Gribouval O, Alamowitch S, et al: COL4A1 mutations and hereditary angiopathy, nephropathy, aneurysms, and muscle cramps. *N Engl J Med* 2007;357:2687–2695.
- 4 Sibon I, Coupry I, Menegon P, et al: COL4A1 mutation in Axenfeld-Rieger anomaly with leukoencephalopathy and stroke. *Ann Neurol* 2007;62:177–184.
- 5 Alamowitch S, Plaisier E, Favrole P, et al: Cerebrovascular disease related to COL4A1 mutations in HANAC syndrome. *Neurology* 2009;73:1873–1882.
- 6 Plaisier E, Chen Z, Gekeler F, et al: Novel COL4A1 mutations associated with HANAC syndrome: a role for the triple helical CB3[IV] domain. *Am J Med Genet A* 2010;152A:2550–2555.
- 7 Weng YC, Sonni A, Labelle-Dumais C, et al: COL4A1 mutations in patients with sporadic late-onset intracerebral hemorrhage. *Ann Neurol* 2012;71:470–477.